



PATIENT

Sasha Martens

SPECIES

Canine

BREED

Shepherd Mix

SEX

Female Spayed

AGE

7 years

WEIGHT

55lbs

INTERPRETED BY

Maggie Machen Lamy, DVM, DACVIM
(Cardiology)

IMAGING PERFORMED BY

HOSPITAL NAME

Mukwonago Animal Hospital

REFERRING VET

Dr. Bittner

INVOICE

20914

DATE

9/7/21

PRESENTING CLINICAL SIGNS

History: Recheck ECG. Historical VPCs with a normal echo (MML 6/2021). A holter done 7/21 showed VPCs with occasional couplets (2208 singles, 3 pairs). No treatment recommended. Current medications: 40mg BID

HOLTER MONITOR FINDINGS AND RHYTHM ASSESSMENT

| | |
|--------------------|--------------|
| Time analyzed | 23:55h |
| Mean heart rate | 68bpm |
| Maximum heart rate | 174bpm |
| Minimum heart rate | 37bpm |
| VPCs | 1591; 1 pair |
| APCs | None |

Interpretation: Underlying normal sinus rhythm with presumably appropriate rate variation (diary not provided). Isolated VPCs throughout; primarily singles, monomorphic. A single couplet identified (inst HR 188bpm). No triplets or VT identified.

Rhythm diagnosis: Sinus rhythm with isolated VPCs; singles with 1 couplet.

RECOMMENDATIONS

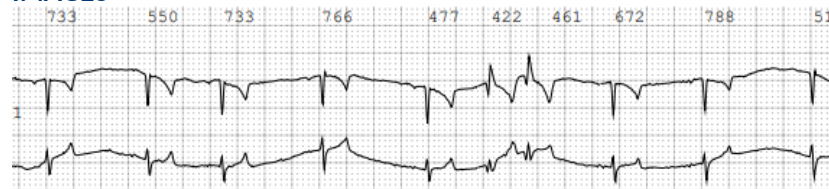
Overall unchanged reading compared to previous. The overall count of VPCs is slightly decreased, with 1 couplet compared to 3. This is of little clinical significance comparatively. No markers of malignancy or other changes identified.

No clear indication for anti-arrhythmic therapy remains. Recommend close monitoring at home for any associated clinical signs including acute lethargy or collapse.

Any animal with VPCs has the risk for sustained arrhythmias such as VT/VF and potential for sudden death.

A recheck ECG and/or holter monitor is recommended in 6 months to screen for progression, sooner if any symptoms such as collapse are noted.

IMAGES



Single couplet

The information and recommendations provided are based on the images presented by the referring veterinarian. No evaluation can be communicated regarding pathology that was not visible in the image/video clips provided.

Thank you for this referral. If the clinical or image interpretation does not parallel your findings or if I can be of any further assistance please contact me.

Maggie Machen Lamy, DVM
Diplomate of the American College of Veterinary Internal Medicine (Cardiology)
info@sonopath.com



PATIENT

Sasha Martens

SPECIES

Canine

BREED

Shepherd Mix

SEX

Female Spayed

AGE

7 years

WEIGHT

55lbs

INTERPRETED BY

Maggie Machen
Lamy, DVM, DACVIM
(Cardiology)

**IMAGING
PERFORMED BY**

HOSPITAL NAME

Mukwonago Animal
Hospital

REFERRING VET

Dr. Bittner

INVOICE

20914

DATE

9/7/21